



CLINICO-PATHOLOGICAL PROFILE OF SALIVARY GLAND TUMORS: INITIAL EXPERIENCE AT A CANCER CENTRE IN SOUTH INDIA

| | |
|----------------------------------|--|
| Dr Sithara Aravind* | Assistant professor, Division of Oncopathology, Malabar Cancer Centre, Thalassery, |
| Dr Sangeetha K Nayanar | Professor, Division of Oncopathology, Malabar Cancer Centre, Thalassery |
| Dr Bithun Balan.K | Post graduate trainee, Dept of Pathology, Kannur Medical College, Thalassery |
| Dr Sujith Kumar M, Former | Assistant professor, Dept of Radiation Oncology, Malabar Cancer Centre, Thalassery |
| Dr Suriy Salih | Former Associate Professor, Dept of Surgical Oncology, Malabar Cancer Centre, Thalassery |

ABSTRACT **Aim:** To analyse the clinico-pathological features of Salivary Gland Tumours (SGT) treated at our centre.

Material and Methods: A retrospective single centre study of 18 months (Jan 2012- June 2013) duration. Data of patients with final diagnosis of SGT were retrieved from Institutional Cancer Registry. The demographic, clinicopathologic, treatment and survival characteristics of this entity is evaluated.

Results: 18 cases of SGT was studied. Median age was 59yrs with female predominance. Parotid gland was the most predominant site (55%). Majority of tumours originated in major salivary glands (61%). 78% were malignant. Acininc cell carcinoma predominated in major and adenoid cystic carcinoma in minor salivary gland. Radical surgery done in 60% of patients. In a short follow up period, (median: 3 months) all patients are alive.

Conclusion: SGT constituted 4% of all Head and Neck tumours, most common site being parotid gland. Acinic cell carcinoma predominates in major and adenoid cystic carcinoma in minor salivary gland.

KEYWORDS

salivary gland, tumours,malignant.

ARTICLE HISTORY

Submitted : 14 January 2018

Accepted : 19 March 2018

Published : 05 July 2018

***Corresponding Author** Dr Sithara Aravind, Assistant professor, Division of Oncopathology, Malabar Cancer Centre,Thalassery, sitharaaravind@gmail.com

INTRODUCTION:

Salivary gland tumour (SGT) is a rare and heterogeneous group of neoplasms constituting 3-10% of head and neck tumors (1). Though rare, they form an important group of oral and maxillofacial pathologic lesions. The relative infrequency of these tumors make their pathological diagnosis and clinical management quite complicated.

Variations in clinico-pathological profile of SGT related to racial and geographic differences have been described in literature. (2,3) We aim to evaluate the South Indian scenario by reviewing our institutional experience. The paucity of data on SGT in South Indian population enhances the relevance of this study.

MATERIALS AND METHODS:

It is a retrospective, single institute study for a period of 18 months. All patients with salivary gland swelling presented in head and neck surgical oncology OPD of our institute from January 2012 to June 2013 are included in the study. Patient details are retrieved from institutional cancer registry and from archives of pathology department. Data analysis is done using the software SPSS V20.

Our aim is to evaluate the demographic, clinicopathologic, treatment and survival characteristics of SGT.

OBSERVATIONS AND RESULTS:

Total 25 cases were studied all of which presented with painless

swelling (100%). Age of the patients ranged from 20 years to 62 years with a median age of 59years. A female predominance (56%) noted with a male to female ratio of 0.8 Of the total cases, 16 (64%) are in major salivary glands (Parotid, submandibular and sublingual) and 9(36%) in minor salivary glands.

There are 5 (20%) benign tumours, 17 (68%) malignant tumours and 3(12%) cases of metastasis from squamous cell carcinoma.

Fig 1: Proportion of salivary gland tumours:

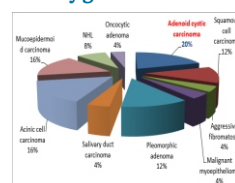


Fig 2: Histologic types in major Salivary Gland: (n=16)

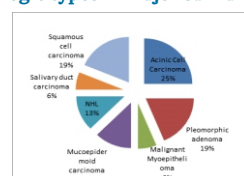
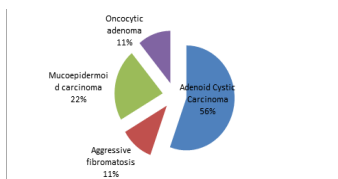


Fig 3: Histologic types in minor Salivary Gland: (n=9)

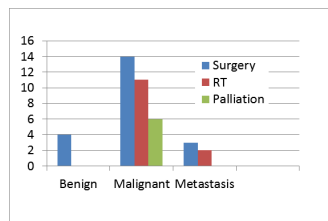


Diagnostic imaging was undertaken in 15 cases, with an Imaging – Histopathology Concordance of 79%.

Diagnostic FNAC was undertaken in 13 cases, with FNAC – Histopathology Concordance of 77%.

Both imageology and FNAC was done in 3 cases with a radio- cyto –histo concordance of 100%.

Fig4 : Treatment modalities



There was a single case (5.8%) with lymph node metastasis and 2 cases (11.7%) with distant metastasis. Both the cases with distant metastasis showed no lymph node involvement.

In a mean follow up period of 3 months, all cases are alive. None of the malignant cases showed recurrence.

Discussion:

Indian data on salivary gland tumours is limited. In our institution SGT constituted 4 % of head and neck tumours.

Literature review has shown that SGT occur over a wide age group. Stewart et al.(4) and Rajwanshi et al.(5) reported age range of 20-92 years and 9-75 years respectively. Our observation was in concordance with the above findings with an age range of 20-62 years.

The female predominance in the present study was in accordance with the study of Frable and Frable (6), Stewart et al(4) and Rajwanshi et al.(5) In our study, parotid gland is the commonest site of occurrence (48%), followed by minor salivary glands (36%), submandibular(12%) and sublingual(4%) glands. This contrasts with majority of major studies (6,7) in which submandibular gland involvement is predominant over minor salivary glands. But our study correlates with the study by Rajwanshi et al. (5)

In the present study 20% cases were diagnosed as benign tumors and 68% cases were diagnosed as primary malignant tumors. This finding is in discordance with most of the published literature including studies by Bradley and McGurk 8 in United Kingdom, Subhashraj(9) in India. However there are a few studies with results similar to our study. Tilakaratne et al (10) has reported an almost equal frequency of benign and malignant tumors and Dhanuthai et al (11) has reported that the number of malignant SGT is slightly more than benign tumors. Predominance of malignant tumours in our study can be attributed to the fact that ours is a tertiary cancer centre.

Fig 5: Adenoid cystic carcinoma H&E 20X

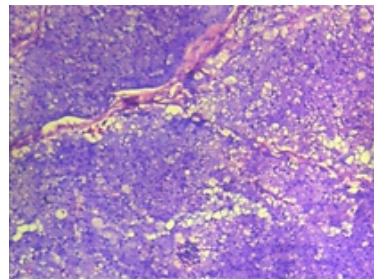
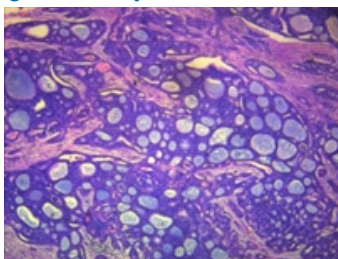


Fig 6: Acinic cell carcinoma H&E -20X

Adenoid cystic carcinoma (ACC) is the most common tumour (20%) as well as the most common malignancy (29%) in our study. This is in concordance with studies by Subhashraj9 in India, and Tain et al (12) in China, where ACC had been reported as a most common malignant salivary gland tumor. In most of the studies conducted in West, Mucoepidermoid Carcinoma(MEC) is the commonest malignant tumour (13,14)

According to the results of the present study, pleomorphic adenoma is the most common benign SGT (60%). High incidence of pleomorphic adenoma (40-80%) has been reported in most of the epidemiological studies.(2,15)

In the study by Robert J et al, ACC is the most common malignant tumour of minor salivary gland and MEC is the most common malignant tumour of major salivary gland (16). In our study acinic cell carcinoma predominates in major salivary gland and ACC in minor salivary glands.

Harriet C. Thoeny, states that the exact pre-operative evaluation of salivary gland tumours remains a major challenge. The differentiation of benign and malignant masses is often impossible by radiological imaging (17) Our study showed a good historadiological concordance of 79%.

Studies by Ritu jain et al and Mihashi H et al have reported a wide range in cyto-histological type agreement rate 30%- 64.2% (18,19) . In our study the cytohistological concordance is 77%.

Well planned and meticulously performed surgery is the primary treatment of malignant tumors of the salivary glands. Depending on specific tumor characteristics and stage, surgery is combined with postoperative radiation therapy (20). Salivary gland neoplasms respond poorly to chemotherapy. Current indication for adjuvant chemotherapy is only for palliation. Doxorubicin- and platinum-based agents are most commonly used. (21) In the present study, 21 cases had undergone definite surgery (4 benign cases, 14 malignant and 3 metastatic cases). 11 malignant cases (64% of malignant lesions) and 2 (66% of metastatic lesions) had received radiotherapy.

According to Bradley PJ, patients developing distant metastases are those with high-grade tumors - commonly adenoid cystic carcinoma, high-grade mucoepidermoid carcinoma, salivary duct carcinoma and tumors sited in the submandibular gland, posterior tongue and pharyngeal tumor.(8) Our observation was similar, with distant metastasis occurring in cases of high grade adenoid cystic and mucoepidermoid carcinoma.

Conclusion:

In our study SGT constituted 4% of all Head and Neck tumours, most common site being parotid gland. A predominance of acinic cell carcinoma was seen in major salivary gland and adenoid cystic carcinoma in minor salivary gland. Predominance of malignant tumors can be attributed to the fact that the study was done in a cancer centre.

Our study is a humble attempt to understand the clinicopathologic pattern of SGT in our area. Limitation of our study is the sample size and short duration.

Nation wide study on salivary gland tumours shall be of great importance in establishing the Indian geographic epidemiology. Racial

differences in clinical and behavioural patterns of tumours mandates further evaluation and modification of specific management protocols based on Indian population.

REFERENCES:

1. . Eveson JW, Cawson RA. Tumours of the minor (oropharyngeal) salivary glands: A demographic study of 336 cases. *J Oral Pathol.* 1985;14:500–9.
2. . Eveson JW, Cawson RA. Salivary gland tumours. A review of 2410 cases with particular reference to histological types, site, age and sex distribution. *JPathol.* 1985;146:51–80.
3. . Main JH, Orr JA, McGurk FM, McComb RJ, Mock D. Salivary gland tumors: Review of 643 cases. *J Oral Pathol.* 1976;5:88–102.
4. . Stewart CJR, Mackenzie K, McGarry GW, Mowat A. Fine needle aspiration cytology of salivary glands: A review of 341 cases. *Diagn Cytopathol.* 2000;22:139-46.
5. . Rajwanshi A, Gupta K, Gupta N, Shukla R, Shrinivasan R, Nijhawan R. Fine needle aspiration cytology of salivary glands: Diagnostic pitfalls- Revisited. *Diagn Cytopathol.* 2006;34:580-84.
6. . Frable MA, Frable WJ. Fine needle aspiration biopsy of salivary glands. *Laryngoscope.* 1991;101: 245-9.
7. . Cristallini EG, Ascani S, Farabi R, Liberati F, Maccio T, Peciarolo A. Fine needle aspiration biopsy of salivary gland 1985-1995. *Acta Cytol.* 1997;41:1421-25.
8. . Bradley PJ, McGurk M. Incidence of salivary gland neoplasms in a defined UK population. *Br J Oral Maxillofac Surg.* 2013;51:399–403.
9. . Subhashraj K. Salivary gland tumors: A single institution experience in India. *Br J Oral Maxillofac Surg.* 2008;46:635–8
10. . Tilakaratne WM, Jayasooriya PR, Tennakoon TM, Saku T. Epithelial salivary tumors in Sri Lanka: A retrospective study of 713 cases. *Oral Surg Oral Med Oral Pathol Oral Radiol Endod.* 2009;108:90–8
11. . Dhanuthai K, Boonadulyarat M, Jaengjongdee T, Jirudee K. A clinico-pathologic study of 311 intra-oral salivary gland tumors in Thais. *J Oral Pathol Med.* 2009;38:495–500
12. . Tian Z, Li L, Wang L, Hu Y, Li J. Salivary gland neoplasms in oral and maxillofacial regions: A 23-year retrospective study of 6982 cases in an eastern Chinese population. *Int J Oral Maxillofac Surg.* 2010;39:235–42.
13. . Bradley PJ, McGurk M. Incidence of salivary gland neoplasms in a defined UK population. *Br J Oral Maxillofac Surg.* 2013;51:399–403
14. . Robert J. McKenna, M.D. *Cancer Journal for Clinicians* vol 34, no 1 January/February 1984
15. . Lukšić I, Virag M, Manojlović S, Macan D. Salivary gland tumours: 25 years of experience from a single institution in Croatia. *J Craniomaxillofac Surg.* 2012;40:e75–81
15. . Barnes L, Eveson JW, Reichart P, Sidransky D. Lyon: IARC Press; 2005. *Pathology and Genetics of Head and Neck Tumours*; pp. 209–82.
16. . Robert J. McKenna, M.D. *ca-a cancer journal for clinicians* vol 34, no 1 january/february 1984
17. . Harriet C. Thoeny Imaging of salivary gland tumours. *Cancer Imaging.* 2007; 7(1): 52–62
18. . Ritu Jain, DNB, Ruchika Gupta, MD, 1 Madhur Kudesia, MD, and Sompal Singh, MD Fine needle aspiration cytology in diagnosis of salivary gland lesions: A study with histologic comparison *Cytojournal.* 2013; 10: 5.
19. . Mihashi H, Kawahara A, Kage M, Kojiro M, Nakashima T, Umeno H, et al. Comparison of preoperative fine-needle aspiration cytology diagnosis and histopathological diagnosis of salivary gland tumors. *Kurume Med J.* 2006;53:23–7
20. . Bell et al. Malignant Salivary Gland Tumors. *J Oral Maxillofac Surg* 2005
21. . Posner MR, Ervin TJ, Weichselbaum RR, et al: Chemotherapy of advanced salivary gland neoplasms. *Cancer* 50:2261, 1982
22. . Bradley PJ. Distant metastases from salivary glands cancer. *ORL J Otorhinolaryngol Relat Spec.* 2001 Jul-Aug;63(4):233-42