



EXTRA CORPOREAL IRRADIATION AND SURGICAL REINFORCEMENT IN PRIMARY MALIGNANT BONE TUMORS: A POOR MAN'S BIOLOGICAL PROSTHESIS

Naveen T	Department of Radiation Oncology Kidwai Memorial Institute of Oncology Hosur Road, Bangalore 560029
Manjula MV	Department of Radiation Oncology Kidwai Memorial Institute of Oncology Hosur Road, Bangalore 560029
YS Pawar	Department of Radiation Oncology Kidwai Memorial Institute of Oncology Hosur Road, Bangalore 560029
Tanveer Pasha	Department of Radiation Oncology Kidwai Memorial Institute of Oncology Hosur Road, Bangalore 560029
Sridhar P	Department of Radiation Oncology Kidwai Memorial Institute of Oncology Hosur Road, Bangalore 560029
Rekha Reddy B	Department of Radiation Oncology Kidwai Memorial Institute of Oncology Hosur Road, Bangalore 560029

ABSTRACT

Limb preserving surgeries are established as oncologically safe and standard of care in the management of primary malignant bone tumors. Surgical resection, extracorporeal irradiation and surgical reimplantation is one among the limb sparing techniques. In our institute, we adopted this method in 9 patients and analysed their oncological outcome. **Materials and Methods** Between 2019 to 2022 Nine patients diagnosed with primary bone tumors after appropriate neoadjuvant chemotherapy, underwent surgical resection and extracorporeal irradiation and surgical fixation. 6 were men and 3 women. 6 patients were diagnosed with ewing's sarcoma and three with Osteogenic sarcoma. The median age was 14years (range 8-20 years). The treated bones were femur (n=4), tibia (n=2), humerus (n=2), iliac bone with acetabulum (n=1). After informed consent and appropriate investigations, patients underwent wide local excision. The resected bone was irradiated with single dose of 50Gy was re-implanted and stabilised with screws and plates. Patients were mobilised with appropriate mechanical aids and referred for completion of chemotherapy. All were followed-up with appropriate imaging. Out of the 9 patients, 1 patient with osteosarcoma after six month of disease free interval developed local recurrence along with distant metastasis. One patient with Ewing's sarcoma had non-union, however the patient was still on adjuvant chemotherapy. The remaining seven patients remained disease free till the last follow-up. The mean musculoskeletal tumour society scoring system (MSTSS) was 3 (range 1-4). **Conclusion** In government aided centres where majority of patients belong to lower socio-economic class, unsupported by health insurance, limb preservation by extracorporeal irradiation can be an alternative modality. ECRT would serve as best size matched, "poormans' biological prosthesis, which is less expensive, readily available and yet maintaining the purpose of limb function.

KEYWORDS

Primary bone tumours, extracorporeal irradiation, Organ preservation, biological prosthesis.

***Corresponding Author YS Pawar** Department of Radiation Oncology Kidwai Memorial Institute of Oncology Hosur Road, Bangalore 560029

Introduction

Primary bone tumors, commonly seen in children and adolescents are rare accounting to approximately 0.5 percent of all cancers in the world.[1] In India, according to Bombay cancer registry, bone malignancies were found to represent 0.9% of all cancers and Ewing sarcoma being commonest.[2] In Karnataka, a retrospective data of 523 bone tumours, collected over 36 years, Osteogenic sarcomas were 45.7% and 19.4% were Ewing's sarcoma.[3] The difference in incidence is due to its rarity.

Historically, limb deforming surgery was the standard of care. Since 1960, with the involvement of inter-disciplinary team in decision making, technological advances in radiation oncology, radiology and newer chemotherapeutic drugs, treatment concept has translated from deforming surgery to limb sparing and function preservation methods. Although, limb preservation using mega prosthesis is commonly practiced, but the associated complications like loosening of implant, implant failure, infection, heaviness of the limb, and cost of the implant are the inevitable sequel. The other methods of limb preservation are adopting biological reconstruction methods.

Re-implantation of devitalised or tumour sterilized bone segment is one of the alternative reconstruction option. The various methods of sterilizing the tumours are autoclave, microwave, pasteurization,

liquid nitrogen, and radiotherapy (extracorporeal radiotherapy).[4-9] The advantage of extracorporeal radiation and re-implantation is being cost effective, convenient yet maintaining the objective of limb preservation. Although the technique was first adopted by Spira et al in 1968 however it was not in regular practice due to lack technical expertise. [10] We are reporting our initial experience and preliminary results of nine patients treated with ECR.

Materials and Methods

From 2019 to 2022, nine patients with histologically proven primary malignant bone tumours were enrolled after obtaining approval from institutional ethical review board. All patients were evaluated in multidisciplinary clinic involving orthopaedic onco-surgeons, radiation oncologists and medical oncologists. Patients were evaluated with complete hemogram, liver and renal function tests. Magnetic resonance imaging (MRI) was performed in all the patients to measure precise extension of the tumour, its relation to neuro-vascular bundle, presence of extra osseous component, involvement of bone marrow and to assess the cortical strength. Computed tomography of thorax and bone scan was done to rule out distant metastasis. PET CT scan was done when ever feasible and required. Patients with Ewing's sarcoma family of tumours underwent bone marrow evaluation as a part metastatic workup. Patients with pathological fracture or compromised bone strength were excluded

for ECRT.

Surgery

The surgery was planned 4 weeks after appropriate neoadjuvant chemotherapy (NACT). Adhering to the oncological principles, en-bloc resection of the tumour with adequate margins was done. The adequacy of the margins was confirmed by frozen section taken from multiple sites. The resected bone segment was given thorough antibiotic wash before it is draped and packed in sterile plastic bags. Adequate measures were taken to avoid any air pockets while packing before sending for irradiation.

Extra-Corporeal Radiation (ECRT)

A dedicated linear accelerator was kept ready, to receive the specimen and execute radiation treatment under aseptic precautions. The specimen received from OT was placed in a water phantom, customised as an irradiator. The phantom was filled with sterile, distilled water used routinely for RFA measurements (figure1). The radiation was delivered using 6MV photons, at maximum dose rate, with parallel opposing beam arrangements. The radiation dose of 50Gy in single fraction at mid plane was prescribed. Based on field dimensions and separation treatment monitor units (MU) were calculated by tissue maximum ratio formula. The radiation was delivered by isocentric (SAD) technique to reduce the treatment time. The turnaround time of radiation ranged between 20-25mins. The bone segment thus irradiated was sent back to OT under aseptic precautions for surgical re-implantation and fixation using plates and screws (figure 2 & 3).

Results

Between Aug 2019 to Dec 2021, Nine patients diagnosed with primary malignant bone tumours were included in this series. Six patients were diagnosed with Ewing's sarcoma and three patients with osteosarcoma. All patients underwent wide local excision, extra-corporeal bone radiation (ECI) and re-implantation of the devitalised bone segment and stabilised with plates and screws. All patients had R0 resection.

The patient demographic details and characteristic features of the disease is mentioned in Table 1. Among the 9 patients, 6 were men and 3 were women. The median age was 14 years (8years – 20 years). Among the 9 patients 6 patients were diagnosed with Ewing's sarcoma and 3 were with Osteosarcoma. The treated bones were femur (n=4), tibia (n=2), humerus (n=2), iliac bone with acetabulum (n=1). The radiation dose delivered was 50Gy in single fraction at midplane. The median turnaround time of radiation delivery (from the time of specimen reaching treatment room to operating theatre) was 12 minutes (9-25minutes).

Patients were permitted to mobilize under supervision with appropriate mechanical assistance. Patients with lower extremity disease, partial guarded weight bearing, walker assisted movement was permitted. Gradual complete weight bearing walking was allowed once the union was confirmed radiologically and as advised by the surgeon. After wound healing and appropriate postoperative rehabilitation, patients were further referred for completion of adjuvant treatment if any and kept on regular follow-up.

Out of the 9 patients, 1 patient having osteosarcoma developed local recurrence along with distant metastasis after six months of disease free interval. One patient with Ewing's sarcoma had non-union however the patient was still on adjuvant chemotherapy. The remaining seven patient remained disease free till the last follow-up. Using modified musculoskeletal tumour society scoring system (MSTSS) the mean score was 3 (range 1-4)

Discussion

The concept of organ preservation and function restoration with optimum quality of life has resulted in paradigm shift in the management of malignant bone tumours from amputation to limb preservation. ECI and reimplantation is one among the limb preservation techniques. This technique was first described by Spirit et al in 1968, followed by few series.[11-17]

The radiobiological advantage of this method is that, the diseased segment of bone is removed out of the body and irradiated to very high

doses with no dose to normal structures. The radiation dose delivered in the range of 50-300Gy is ablative and tumouricidal, with no dose to the surrounding normal tissues and thereby achieving maximum therapeutic gain.

The biological advantage of ECI is that, it is one of the best anatomically size-matched bone grafts for reconstruction. This procedure is cost-effective also provides psychological support to the patients that their own bone is being used as prosthesis.

The graft infection and failure rates were similar to any other grafts. The risk of wound infection documented in a case series is approximately 17 %.[12,16] In our study, none of the patients had wound site infection. As the wound infection can result in delayed healing, delayed union or non-union, even the failure of graft, consequentially causing delay in adjuvant chemotherapy. Therefore meticulous aseptic precautions should be practiced at all the steps.

We preferred to restrict our radiation doses to 50Gy, as the doses beyond 50Gy is not required to sterilise the tumour, also higher doses are associated with possible detrimental effects such as delayed revascularisation, reduction in bone strength, delayed union and bone incorporation of the graft.[10,13,18,19]

Local recurrence has been rarely reported after extracorporeal irradiation.[20] In our study one patient with osteosarcoma had local recurrence along with multiple distant metastases.


The mean revised Musculoskeletal Tumour Society Score was 3 (1-4) in our study, which was comparable with other series.

The potential drawback of extracorporeal irradiation is the lack of information of tumour response to the chemotherapy and adequacy of the margins which are both predictive and prognostic factors.

Conclusion:

Reconstructing large surgical gaps following tumour resection has always been challenging. In the large volume centres, with limited resources, where in majority of patients belong to lower socio-economic class having no health insurance coverage, ECRT would serve as best size matched, "poormans' biological prosthesis, which is less expensive, readily available and yet maintaining the purpose of limb function.

Figure 1: - ECRT set-up with a water phantom customised as bone irradiator.



(figure: 2 & 3):- Post operative images of bone segment fixed using nails and screws

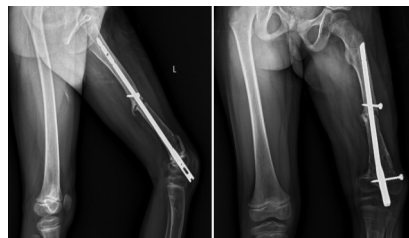


Table 1: Patients demographics (n=9)

Sl No	Age (yrs)	Sex	Histology	Primary Site	Radiation Dose	Local Disease status	Distant Metastasis	Local Complications
1	20	M	ES	Femur	50 Gy	NED	NO	NIL
2	20	F	OS	Femur	50Gy	NED	NO	NIL
3	19	M	ES	Ilium	50Gy	NED	NO	NIL
4	14	F	ES	Tibia	50Gy	NED	NO	NIL

5	10	M	ES				NO	NIL
6	11	M	OS	Tibia	50Gy	Reurrence	Lung Metastasis on metronomic chemotherapy	--
7	8	F	ES	Humerus	50Gy	Pathological Fracture/ Non union	On Adjuvant chemotherapy	--
8	10	M	ES	Tibia	50Fy	NED	NO	NIL
9	17	M	OS	Radius	50Gy	NED	NO	NIL

M=Male,F=Female,ES=Ewings'sarcoma,OS=Osteogenicsarcoma,NE D=No evidence of disease.

REFERENCES

- Karun Jain 1, Sunila, R Ravishankar, Mruthyunjaya et al. Bone tumors in a tertiary care hospital of south India: A review 117 cases. Indian J Med PaediatrOncol 2011;32:82-85.
- Yeole BB, Jussawalla DJ. Descriptive epidemiology of bone cancer in greater Bombay. Indian J Cancer 1998;35:101-106
- Rao VS, Pai MR, Rao RC, Adhikary MM. Incidence of primary bone tumours and tumour like lesions in and around Dakshina Kannada district of Karnataka. J Indian Med Assoc 1996;94:103-104, 121
- Hurson BJ (1995) Limb-sparing surgery for patients with sarcomas [editorial]. J Bone Joint Surg Br 77:173-17.
- Hong A, Stevens G, Stalley P, Pendlebury S, Ahern V, Ralston A, et al. Extracorporeal irradiation for malignant bone tumors. Int J Radiat Oncol Biol Phys 2001;50:441-7.
- Bohm P, Springfield R, Springer H. Re-implantation of autoclaved bone segments in musculoskeletal tumor surgery. Clinical experience in 9 patients followed for 1.1-8.4 years and review of the literature. Arch Orthop Trauma Surg 1998;118:57-65.
- Manabe J, Ahmed AR, Kawaguchi N, Matsumoto S, Kuroda H. Pasteurized autologous bone graft in surgery for bone and soft tissue sarcoma. Clin Orthop Relat Res 2004;258-66.
- Anacak Y, Sabah D, Demirci S, Kamer S. Intraoperative extracorporeal irradiation and re-implantation of involved bone for the treatment of musculoskeletal tumors. J Exp Clin Cancer Res 2007;26:571-4. 14. Lu S, Wang J, Hu Y. Limb salvage in primary malignant bone tumors by intraoperative microwave heat treatment. Chin Med J (Engl) 1996;109:432-6.
- Lu S, Wang J, Hu Y. Limb salvage in primary malignant bone tumors by intraoperative microwave heat treatment. Chin Med J (Engl) 1996;109:432-6
- Spira E, Lubin E. Extracorporeal irradiation of bone tumors. A preliminary report. Isr J Med Sci 1968;4:1015-9.
- Uyttendaele D, De Schryver A, Claessens H, Roels H, Berkvens P, Mondelaers W. Limb conservation in primary bone tumours by resection, extracorporeal irradiation and re-implantation. J Bone Joint Surg Br 1988;70:348-53.
- Araki N, Myoui A, Kuratsu S, Hashimoto N, Inoue T, Kudawara I, et al. Intraoperative extracorporeal autogenous irradiated bone grafts in tumor surgery. Clin Orthop Relat Res 1999 Nov;368:196-206.
- Hong A, Stevens G, Stalley P, Pendlebury S, Ahern V, Ralston A, et al. Extracorporeal irradiation for malignant bone tumors. Int J Radiat Oncol Biol Phys 2001;50:441-7.
- Chen WM, Chen TH, Huang CK, Chiang CC, Lo WH. Treatment of malignant bone tumours by extracorporeally irradiated autograft-prosthetic composite arthroplasty. J Bone Joint Surg Br 2002;84:1156-61.
- Davidson AW, Hong A, McCarthy SW, Stalley PD. En-bloc resection, extracorporeal irradiation, and re-implantation in limb salvage for bony malignancies. J Bone Joint Surg Br 2005;87:851-7.
- Puri A, Gulia A, Agarwal M, Jambhekar N, Laskar S. Extracorporeal irradiated tumor bone: A reconstruction option in diaphyseal Ewing's sarcomas. Indian J Orthop 2010;44:390-6.
- Poffyn B, Sys G, Mulliez A, Van Maele G, Van Hoorebeke L, Forsyth R, et al. Extracorporeally irradiated autografts for the treatment of bone tumours: Tips and tricks. Int Orthop 2011;35:889-95.
- Davidson AW, Hong A, McCarthy SW, Stalley PD. En-bloc resection, extracorporeal irradiation, and re-implantation in limb salvage for bony malignancies. J Bone Joint Surg Br 2005;87:851-7.
- Currey JD, Foreman J, Laketic I, Mitchell J, Pegg DE, Reilly GC. Effects of ionizing radiation on the mechanical properties of human bone. J Orthop Res 1997;15:111-7.
- Chen TH, Chen WM, Huang CK. Reconstruction after intercalary resection of malignant bone tumours: Comparison between segmental allograft and extracorporeally-irradiated autograft. J Bone Joint Surg Br 2005;87:704-9.